

Ultrasonographic findings of some ocular structures in Caspian miniature horse

Soroori, S.¹; Masoudifard, M.^{1*}; Raoofi, A.¹
and Aghazadeh, M.²

¹Department of Clinical Sciences, Faculty of Veterinary Medicine, University of Tehran, Tehran, Iran;

²Graduated from Faculty of Veterinary Medicine, University of Tehran, Tehran, Iran

*Correspondence: M. Masoudifard, Department of Clinical Sciences, Faculty of Veterinary Medicine, University of Tehran, Tehran, Iran. E-mail: mmfard@ut.ac.ir

(Received 30 Nov 2008; revised version 8 Jun 2009; accepted 5 Jul 2009)

Summary

Ultrasonography is a relatively easy, safe and non-invasive examination method which can be used in diagnosis of ocular disorders as complementary to routine ophthalmic examinations. As there has been no collated study undertaken on the normal measurements of ocular structures in Caspian miniature horse, obtaining these measurements could be a benchmark to diagnose some of the diseases and eye problems of this miniature breed. Transpalpebral ultrasonographic scanning of left and right eyes of six Caspian horses was performed using a 10-13 MHz transducer. Qualitative ultrasonographic findings of the eyes were described and measurements of the ocular structures were obtained. Mean \pm standard deviation of the anterior-posterior length of the eye axis, thickness of the lens, depth of the anterior chamber and depth of vitreous were as 32.9 ± 1.0 , 10.8 ± 0.8 , 3.0 ± 0.5 and 18.3 ± 1.0 mm, respectively.

Key words: Caspian horse, Ultrasonography, Eye

Introduction

The Caspian miniature horse is an ancient breed previously believed to have been extinct for over one thousand years. This small horse is extremely rare and is probably a direct ancestor of the oriental breeds and subsequently of all light horse breeds (Hendricks, 1995).

Ocular ultrasonography as a diagnostic tool includes both amplitude mode (A-mode) and brightness mode (B-mode). In veterinary ophthalmology, B-mode ultrasound provides a two-dimensional real-time image and is the most common mode of ultrasound in a clinical setting. Ultrasonography is a safe, non-invasive and painless method of examining intraocular and retrobulbar structures that may be obscured by certain pathologic conditions and undetectable using ordinary light sources or ophthalmoscopy, especially in animals that are awake as in cases when little preparation of the patient is necessary.

This technique is indicated whenever opacity of the transmitting media of the eye (cornea, aqueous humor, lens and vitreous humor) prevents a complete ophthalmic examination (Rogers *et al.*, 1986; Williams and Wilkie, 1996; Wilkie and Gilger, 1998; Gonzalez *et al.*, 2001).

As there has been no collated study in veterinary medical literature about the normal measurements of eye structures in Caspian miniature horse, obtaining these measurements could be a benchmark to diagnose some of the diseases and eye problems of this miniature breed. Knowledge of the ultrasonographic appearance of the equine intraocular structures would serve as a base from which clinical examination of the equine eye might be done. Knowledge of the normal dimensions of the equine eye and its intraocular structures during an ultrasound exam would be helpful in assessing possible alterations in these dimensions due to a disease process.

Abnormalities of globe dimensions include enlargement of the globe (buphthalmos), decrease in globe size (microphthalmos, phthisis bulbi), increased or decreased lens dimensions, and changes in the relationships of intraocular structures with each other (Wilkie and Gilger, 1998).

The objectives of this study were: 1) to present the B-mode ultrasonographic appearance of the globe and intraocular structures of the Caspian horse eye, 2) to present the ultrasonographic measurements of the globe and intraocular structures of the Caspian horse eye.

Materials and Methods

The left and right eyes of six pure registered healthy adult Caspian horses (5 females and 1 male) which had no history or clinical signs of eye problems were scanned ultrasonographically using a Sonosite Micromax ultrasound machine (Sonosite, Inc., Bothell, WA 98021 USA) with a linear array transducer of 10-13 MHz. At the beginning, acepromazine (0.3-0.4 mg/kg) and xylazine (0.05-0.1 mg/kg) were used to calm down and relax the horses. To avoid trapping air between the transducer and the patient, the palpebral hair was thoroughly wetted before the acoustic gel was applied. After using enough gel on the upper eyelids, transpalpebral scanning was started while the globe was imaged in both horizontal and vertical planes through the visual axis on the upper eyelid parallel and perpendicular to the upper palpebral fissure respectively for a complete examination. This produces a cross-sectional image of the eye with the medial canthus to the right and lateral canthus to the left of the horizontal images. Attempts were made not to cause pressure on the cornea during placement of the transducer on the eyelid. In this method the structure of the eye was evaluated at a depth of 4-6 cm. The gain was set so that there was an anechoic region between the anterior and posterior lens capsule. After examination, each eyelid was gently flushed with sterile saline to remove coupling gel and associated debris. All of the scanning processes were recorded on the memory card of the ultrasound machine and DVD recorder for

further investigation. The best and clearest images were extracted and stored.

Ultrasonographic appearance of the Caspian horse eye was described and dimensions of the globe and intraocular structures including anterior-posterior length of the eye axis (APL), diameter (thickness) of the lens (LD), depth of the anterior chamber (DAC) and depth of vitreous (DV) were measured in captured images using Scion Image Software (Beta version 4-0-3). For each horse, 20 images were evaluated for the right and left eye separately. The measurements were achieved on sonograms of the horizontal planes. All measurements (APL, LD, DAC and DV) were made by the same observer. The means and standard deviations (SD) for each set of measurements were calculated. A statistical comparison of left and right eye measurements was also done using Wilcoxon Signed Rank Test.

Results

In B-mode ultrasonography, four major echoes i.e. cornea, anterior lens capsule, posterior lens capsule and retina-choroid-sclera complex were easily seen.

The cornea was represented as a curved hyperechoic interface immediately under the eyelid. In some of the sonograms, the cornea could be seen as three thin layers, in which the anterior and posterior layers were quite hyperechoic and the middle layer appeared anechoic (Fig. 1).

Anterior chamber of the eye, lens cortex and nucleus and the vitreous were anechoic just like other horse breeds. In some of the images, the optic nerve appeared as a hypoechoic structure posterior to the optic disc in the retrobulbar region. Other echoic structures including ciliary body, iris, corpora nigra and optic disc could also be distinguished (Fig. 1).

Although the obtained images of the horizontal and vertical planes were similar, acquisition of the interpretable sonograms was more easily done in horizontal planes.

The results of the measurements on the right and left eyes of the Caspian horses are shown in Table 1.

No significant difference ($P>0.05$) was

found between the measurements taken from the left and right eyes of the Caspian horse. Total average and standard deviation of the left and right eye measurements are also shown in Table 1.

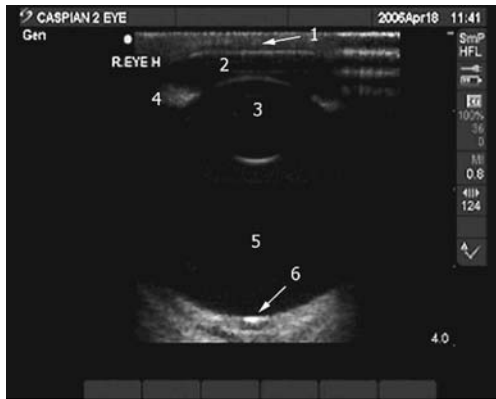


Fig. 1: Transpalpebral ultrasonographic image of normal eye in Caspian horse, obtained by means of a linear transducer of 10-13 MHz, placed horizontally on the eyelid. 1: Cornea, 2: Anterior chamber, 3: Lens, 4: Iris and ciliary body, 5: Vitreous, and 6: Optic disc

Table 1: Mean and standard deviation (SD*) of ocular component measurements (mm) obtained from ultrasonographic images in Caspian horse

	Right eye	Left eye	Total
APL	32.8 (0.8)	33.0 (1.2)	32.9 (1.0)
LD	10.6 (0.7)	11.0 (0.8)	10.8 (0.8)
DAC	3.2 (0.4)	2.7 (0.6)	3.0 (0.5)
DV	18.2 (0.9)	18.3 (1.2)	18.3 (1.0)

*Standard deviation, APL: anterior-posterior length of the eye axis, LD: lens diameter (thickness), DAC: depth of anterior chamber and DV: depth of vitreous

Discussion

Ocular ultrasound is an addition to, not a replacement for, routine ophthalmic examination including assessment of menace, blink and papillary light response, fluorescein staining, nasolacrimal evaluation, determination of intraocular pressure, and examination of anterior and posterior segments using a bright focal light source and direct and indirect ophthalmoscopy or biomicroscopy, respectively (Hillyer, 1993; Reef, 1998; Wilkie and Gilger, 1998; Gonzalez *et al.*,

2001).

The most common clinical indications for ocular ultrasound are to evaluate for the presence of a retinal detachment in eyes with a cataract, intraocular lesions including lens displacement, intravitreal hemorrhage and intraocular foreign bodies. In addition, orbital evaluation can be performed in instances of exophthalmos or orbital trauma (Miller, 1991; Hillyer, 1993; Wilkie and Gilger, 1998). Freestone *et al.* (1989) was able to identify a retrobulbar tumor in an Arab horse. They stated that the nature of the tumor (cystic, angiomatous, solid and infiltrative) was distinguishable by using ultrasonography. Read and Barnett (1995) have also reported equine glaucoma diagnosed by ultrasonography and found it very useful in detecting bophthalmia following glaucoma. In addition to being a diagnostic tool, ultrasound can be used to monitor the progression of a disease or monitor response to therapy (Miller, 1991; Nelms *et al.*, 1993).

There are two techniques for scanning the equine eye: transpalpebral (through the eyelids) which was used in this study, and transcorneal which involves the transducer and coupling gel being applied directly to the corneal surface. In the latter technique, the acoustic gel needs to be sterile, nonirritant and water soluble, although the technique carries a theoretically increased risk of corneal damage. This is outweighed by the enhanced image quality (Hillyer, 1993). Transpalpebral imaging increases artifacts and reduces image quality but may be desirable where the possibility exists of further damage to the cornea through direct probe contact (Read and Barnett, 1995).

Concerning the size of the anterior chamber, it is necessary to mention that transducer pressure on the eyelid can change its real size in the ultrasonographic procedure, since it is a sign of some eye diseases, like keratoconus or staphiloma, and this can mislead the clinician to a wrong diagnosis.

Several studies have been done on the eye ultrasonography in different breeds of horses. However, to the authors' knowledge, this might be the first clinical protocol in which ultrasonography was used in Caspian miniature horses' eyes. Generally, no

difference was found between the Caspian horse eye and other horse breeds in the ultrasonographic appearance of ocular structures (Rogers *et al.*, 1986; Miller, 1991; Hillyer, 1993; Wilkie and Gilger, 1998; Gonzalez *et al.*, 2001). In the study reported here, APL, LD, DAC and DV were measured in normal eyes of Caspian horses to establish mean values and to make comparisons with values reported for full-sized horses and other miniature horses. Axial dimensions of globes in full-sized horses with normal eyes have been measured via A-scan biometry; the ocular component measurements obtained included DAC mean: 5.4 mm, LD mean: 10.6 mm, DV mean: 21.2 mm, and APL mean: 37.2 mm (Ramsey *et al.*, 2000). The mean measurement of DAC, LD, DV and APL in American miniature horses using a 10 MHz A-scan transducer has also been reported to be 5.6, 10.3, 17.8 and 33.7 mm, respectively (Plummer *et al.*, 2003). The Mean of measurements were smaller in Caspian horses (DAC: 2.9, DV: 18.3 and APL: 32.0 mm) compared with values for full-sized horses, although LD measurement (10.8 mm) seemed to be almost similar.

Furthermore, ocular measurements of Caspian miniature horse and American miniature horse were approximately the same, except for the DAC which was smaller in Caspian horses. Rogers *et al.* (1986) have reported B-mode ultrasonography and measurement of the anterior to posterior diameters of the intraocular structures and of the axis bulbi on 95 equine cadaver eyes submerged in a water bath. The obtained data in their study were also different from our measurements.

No difference was detected in any ocular component measurement between the right and left eyes of the Caspian horses. It was in agreement with other investigations (Rogers *et al.*, 1986; Plummer *et al.*, 2003).

With the exception of the overall size of the globe and internal structures, the ultrasonographic appearance and echotexture of the Caspian horse eye was similar to that described in other equines (Rogers *et al.*, 1986; Miller, 1991; Hillyer, 1993; Wilkie and Gilger, 1998).

Acknowledgement

The authors would like to acknowledge the financial support of Deputy of Research, Faculty of Veterinary Medicine, University of Tehran.

References

- Freestone, JF; Glaze, MB; Pechman, R and McClure, JR (1989). Ultrasonic identification of an orbital tumour in a horse. *Equine Vet. J.*, 21: 135-136.
- Gonzalez, EM; Rodriguez, A and Garcia, I (2001). Review of ocular ultrasonography. *Vet. Radiol. Ultrasound.* 42: 485-495.
- Hendricks, BL (1995). *International encyclopedia of horse breeds*. 1st Edn., Oklahoma, University of Oklahoma Press, Norman, Publishing Division of the University. PP: 112-114.
- Hillyer, MH (1993). Ocular ultrasonography in the horse. In: Raw, ME and Parkinson, TJ (Eds.), *The veterinary annual*. (33rd Edn.), Oxford, Blackwell Scientific Publications. PP: 131-137.
- Miller, WW (1991). Diagnostic ultrasound in equine ophthalmology. *Proc. Am. Assoc. Equine Pract.*, 36: 559-565.
- Nelms, SR; Nasisse, MP; Davidson, MG and Kirschner, SE (1993). Hyphema associated with retinal disease in dogs: 17 cases (1986-1991). *J. Am. Vet. Med. Assoc.*, 202: 1289-1292.
- Plummer, CE; Ramsey, DT and Hauptman, JG (2003). Assessment of corneal thickness, intraocular pressure, optical corneal diameter, and axial globe dimensions in Miniature Horses. *Am. J. Vet. Res.*, 64: 661-665.
- Ramsey, DT; Mutti, DO; Zadnik, C; Bullimore, MA and Murphy, CJ (2000). Refractive error in Rocky Mountain horses with cornea globosa and with normal corneas. *Invest. Ophthalmol. Vis. Sci.*, 41: 135.
- Read, RA and Barnett, KC (1995). Equine glaucoma diagnosed with the aid of ultrasonography. *Equine Vet. Educ.*, 7: 225-228.
- Reef, VB (1998). *Equine diagnostic ultrasound*. 1st Edn., Philadelphia, W. B. Saunders Co., PP: 481-536.
- Rogers, M; Cartee, RE; Miller, W and Ibrahim, AK (1986). Evaluation of extirpated equine eye using B-mode ultrasonography. *Vet. Radiol.*, 27: 24-29.
- Wilkie, DA and Gilger, BC (1998). Equine diagnostic ocular ultrasonography. In:

Rantanen, NW and Mckinnon, AO (Eds.),
Equine diagnostic ultrasonography. (1st
Edn.), Baltimore, Williams and Wilkins. PP:
637-643.

Williams, J and Wilkie, DA (1996).
Ultrasonography of the eye. *Comp. Cont.
Educ. Pract. Vet.*, 18: 667-676.

Archive of SID